
Odisee
DE CO-HOGESCHOOL

Sense and nonsense of patient shielding

Liesbeth Eloot

Joint ABR/BVS - BHPA session

BHPA symposium 2022

Odisee
DE CO-HOGESCHOOL

What's the fuss about ?

"Loden schort helpt niet tegen röntgenstraling"

16/01/2020 om 03:00 door jvr - Print - Corrigeer

The New York Times

AAPM

POLICY NUMBER	POLICY NAME	POLICY DATE
PP 32-A	AAPM Position Statement on the Use of Patient Gonadal and Fetal Shielding	4/2/2019

[1]

Het gaat al decennia zo: bevindt u zich in een ruimte waar röntgenfoto's worden genomen, dan krijgt u door het ziekenhuispersoneel een zware loden schort omgegord. Omdat lood de straling tegenhoudt en zo voortplantingsorganen of eventuele zwangere buiken beschermt. Alleen blijkt dat helemaal niet te kloppen, schrijft *The New York Times*.

AAPM Position Statement on the Use of Patient Gonadal and Fetal Shielding

- Endorsed by ACR, NCRP, BIR, NCR
- EFOMP-EFRS-ESR-ESPR-EuroSafeImaging-EURADOS-EADMFR consensus statement
- Despite widespread use ?

Historical perspective

- Publication on discovery of X-rays (1895)
  - +14 days: first dental radiograph by F. O. Walkhoff
  - 1896: 30 patients, 30’ ~ 3Gy : loss of hair
- First users
  - Potential harmful effects of X-rays
- Concerns about
  1. Hereditary effects
  2. Harmful effects on the fetus
  3. Cancer risk

[2]

Gonad shielding

First research into hereditary effects

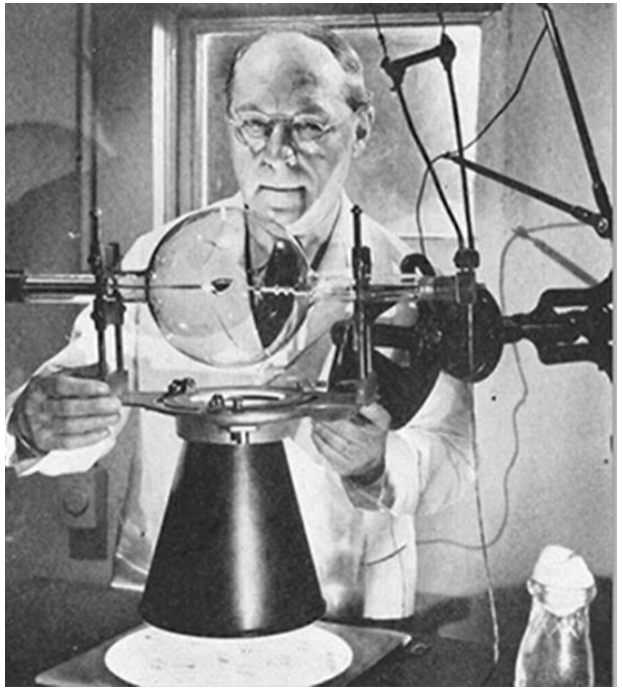

[3]

- 1927
  - Dr. Hermann Joseph Muller
  - High doses of X-rays
  - Drosophila

- 1946
  - Nobel prize for the discovery of induction of mutations after exposure to X-rays

History ~ hereditary effects

- Experiments with insects and small mammals
- After 1945: public interest

- 1950s: Paul C. Hodges
  - Extrapolation of data to humans
  - Use of gonad shielding recommended



[4]

History ~ hereditary effects

- 1970s : guidelines, legislation, education

Food and Drug Administration
[21 CFR Part 1000]
[Docket No. 75N-0148]
SPECIFIC AREA GONAD SHIELDING

"It...protects the germinal tissue of patients from radiation exposure that may cause genetic mutations..."

"Gonadal shielding should only be used when the clinical objectives of the exam will not be compromised."

FEDERAL GUIDANCE REPORT NO. 9
October 1976

Operator Responsibility:
"...to properly collimate the X-ray beam and to use shielding where appropriate and practicable."

Gonad shielding

- 2022 …
  1. Hereditary effects after diagnostic exposures have not been observed
  2. Dose per exam decreased dramatically

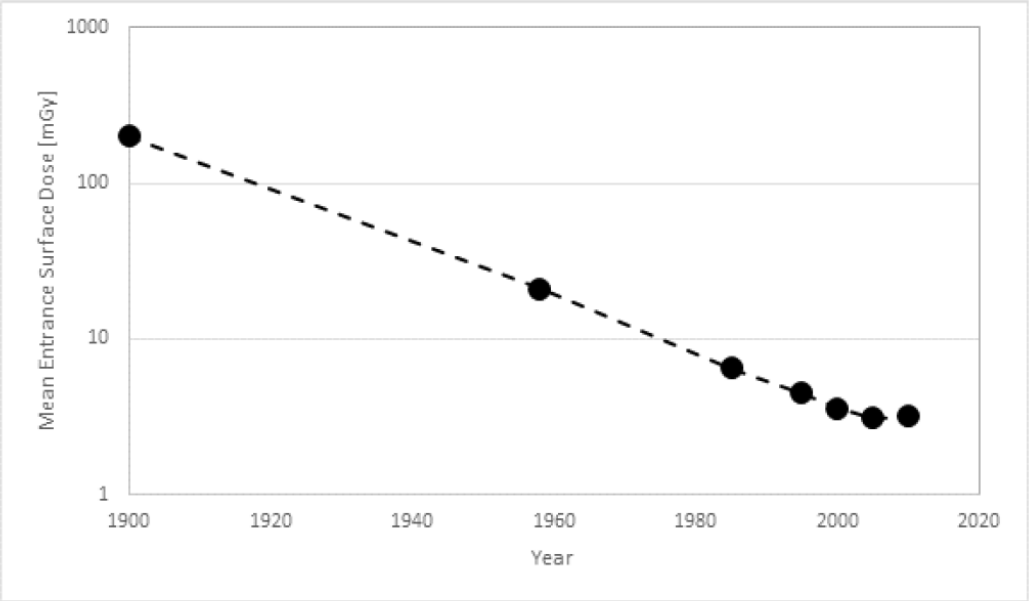

Figure 3.1 Example change in mean entrance surface dose values with time for an AP Pelvis radiograph. Based on doses reported in the literature.[1,2,3]

[5]

Gonad shielding

- 2022 …
  1. Hereditary effects after diagnostic exposures have not been observed
  2. Dose per exam decreased dramatically
  3. Progressive insight into radiation sensitivity of organs and tissues

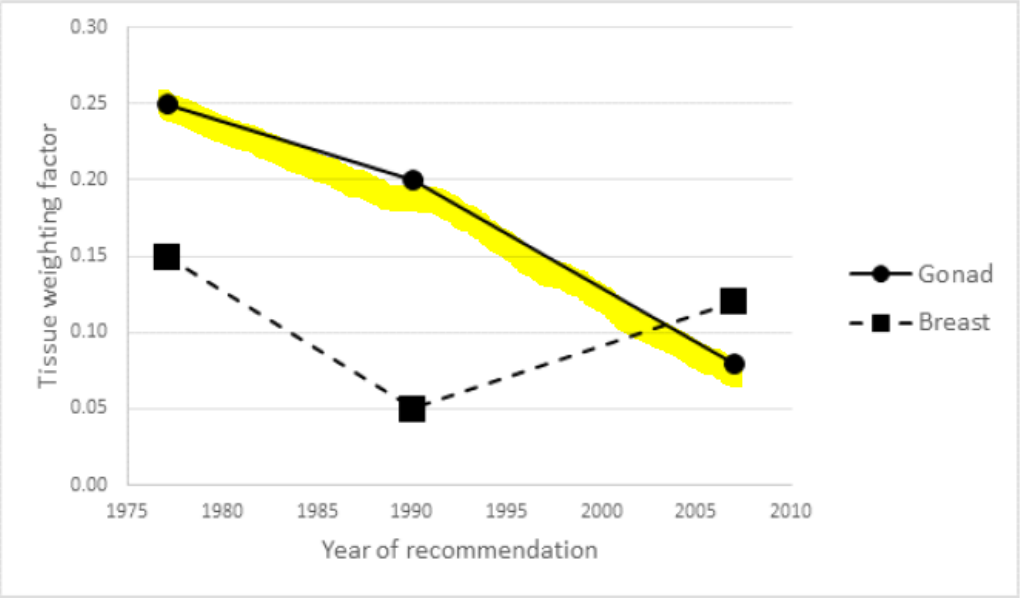

Figure 3.2 Tissue weighting factor versus year of recommendation by the ICRP for two particular tissue types.[4, 5, 6]

[5]

Gonad shielding

- 2022 …
  1. Hereditary effects after diagnostic exposures have not been observed
  2. Dose per exam decreased dramatically
  3. Progressive insight into radiation sensitivity of organs and tissues

4. Effectiveness of gonad shielding limited in practice
   - Within 1° beam

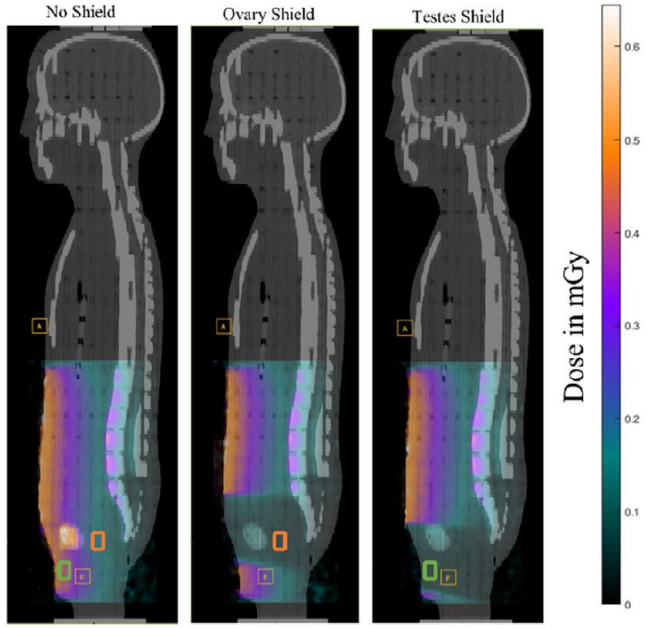

[6]

testes

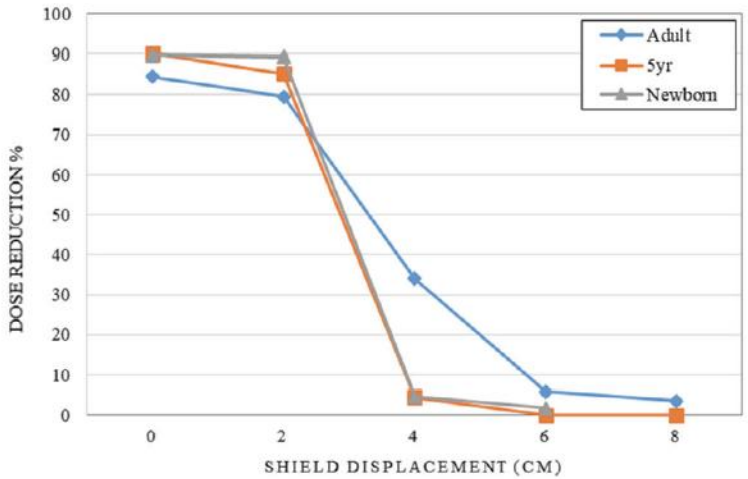

ovaria

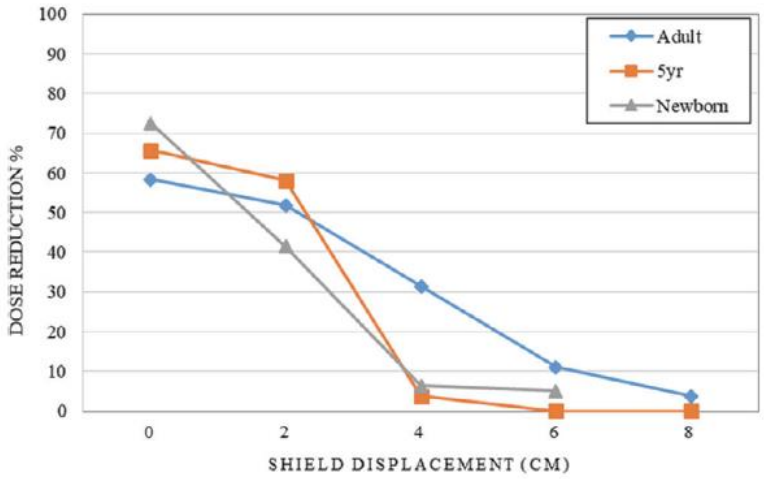

Odisee
DE CO-HOGESCHOOL

Gonad shielding

- Within 1° beam
  - Location of ovaria
  - Cover relevant anatomy
  - Artifacts ~ image quality

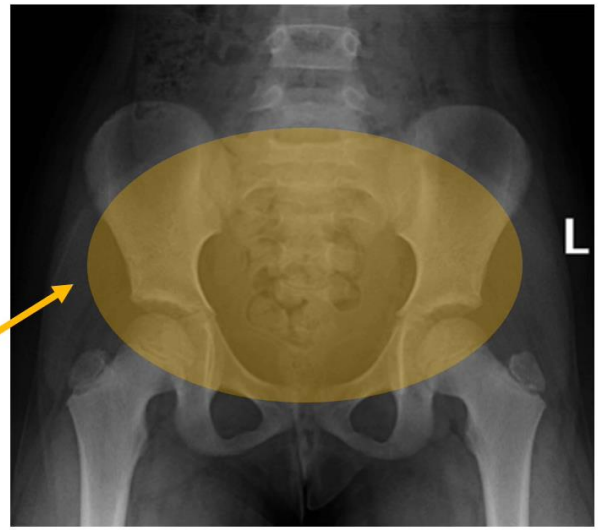

Variations in ovary location

adapted from data in ME Bardo, et al. Ped Rad (2009) 39:253-259.

[7]

Retakes !

Gonad shielding

- Within 1° beam
  - Location of ovaria
  - Cover relevant anatomy
  - Artifacts ~ image quality
    - → retakes

!

- Use of
  - Automatic exposure control (AEC)
  - Automatic brightness control (ABC)
  - Automatic dose rate control (ADRC)
  - Tube current modulation (TCM)

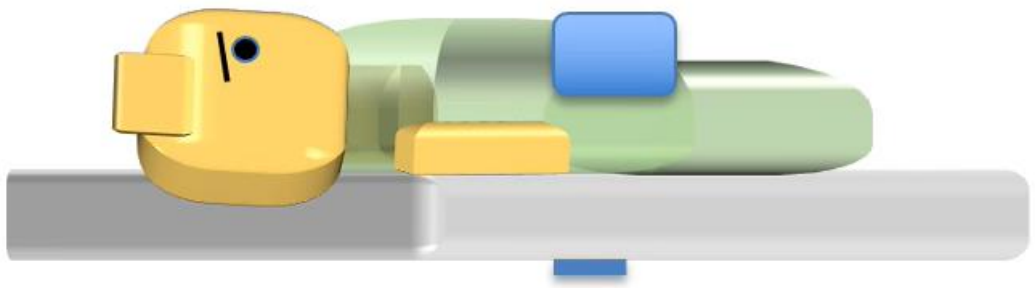

Tube current ↗↗

Gonad shielding

- Within 1° beam
- Outside 1° beam
  - External scatter: order of magnitude max # µGy/s
  - Internal scatter:
    - ↘ with distance to 1° field
    - ↘ with depth in patient

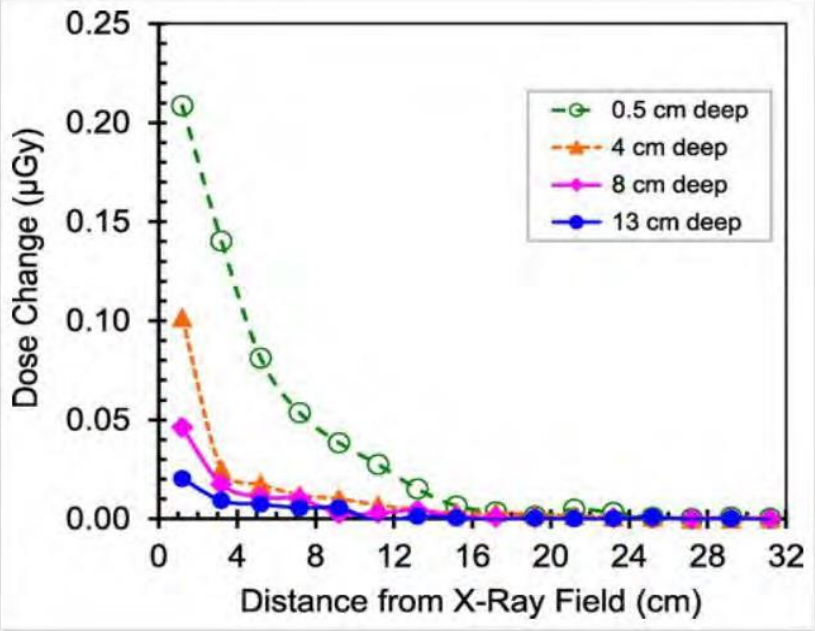

[5]

% of 1° beam

0.002%

0.2%

0.02%

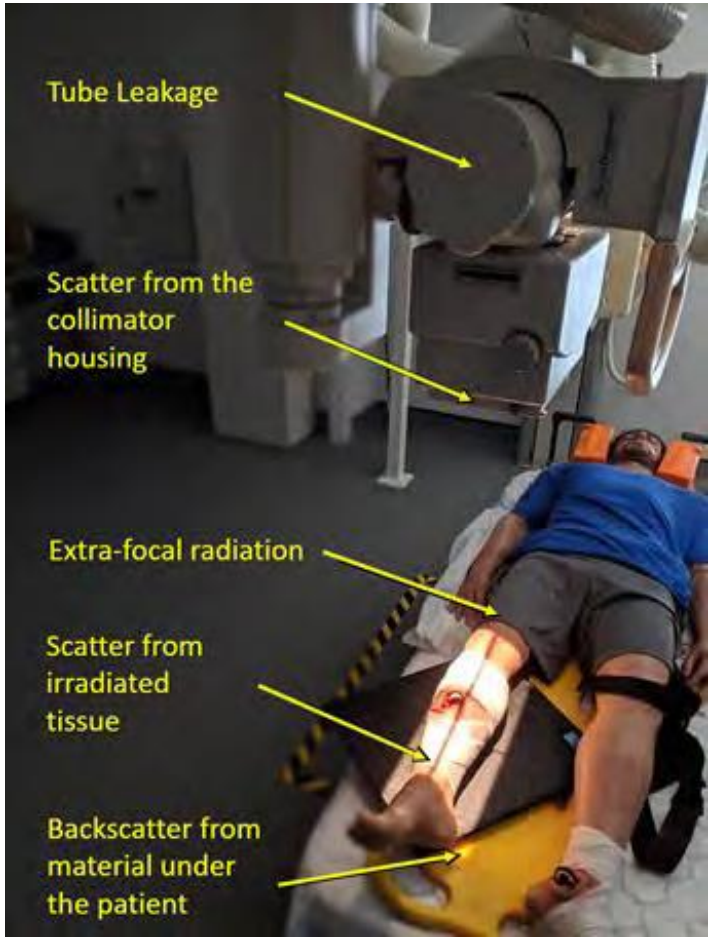

[5]

Gonad shielding: conclusion

1. Has no or negligible benefit to patient health
   - Absolute value of risk reduction is very limited

2. Could have a negative effect on exam
   - Possibly obstructive for exam
   - High chance on increased dose / repeat exam

Should use

May use

Not recommended

[1,5,8]

2. Protection of the unborn child

Risk in utero

- Stochastic effects → part 3
- Deterministic effects
  - Lethal effects
  - Malformations, retardation
  - Risk ↗ with exposure to acute doses above 100 mGy
  - Risk depends on stage of pregnancy
  - Fetal dose ~ quantity and quality of beam
    ~ position relative to 1° beam

Baseline Risks

- ~20%[1]
- 3%-5%[2]

Embryo / Fetal shielding

Within 1° beam

Typical doses without lead protection

- Abdomen/pelvis X-ray < 1-3 mGy
- Fluoro/angio: ! for longer procedures
- CT abdomen/pelvis: up to 20 mGy

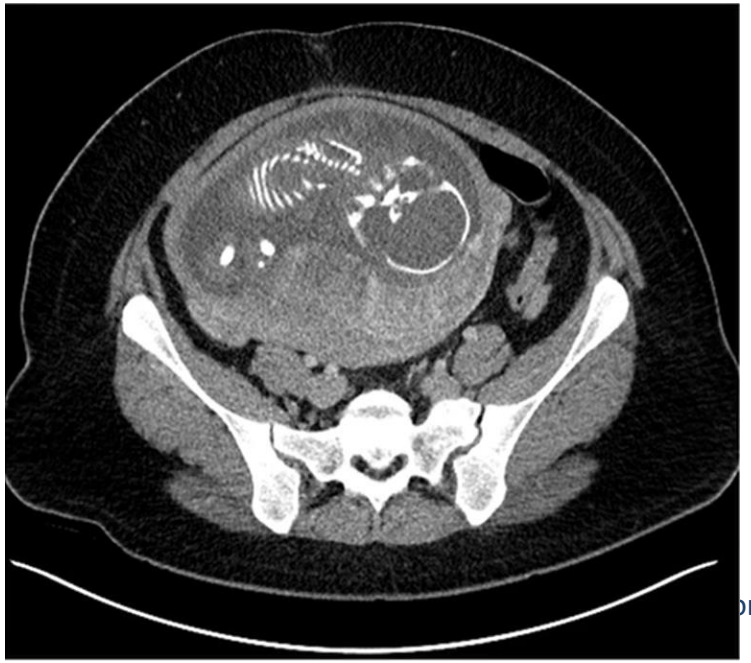

Embryo / Fetal shielding

Within 1° beam

- *Typical* doses
- Risks:
  - AEC / ABC / ADRC / TCM: dose ↗↗
  - Artifacts / image quality
  - Cover relevant anatomy

→ Repeat exam

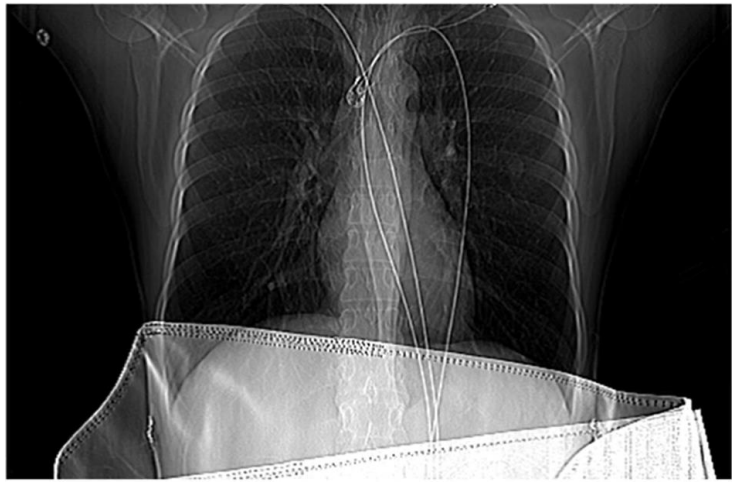

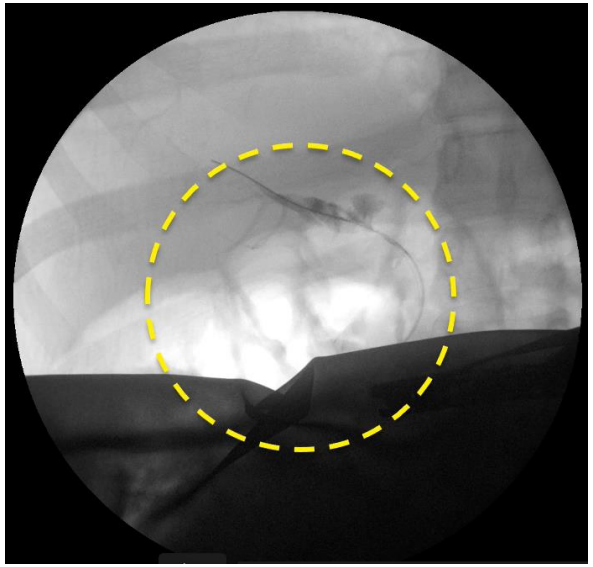

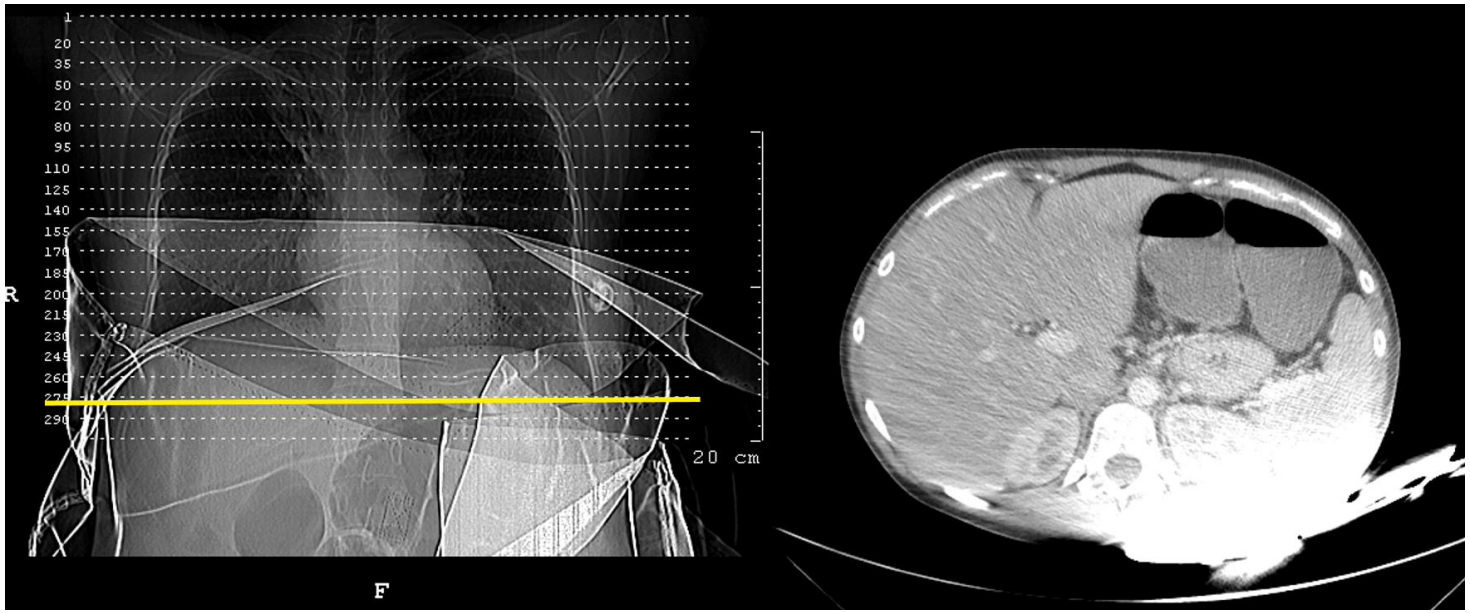

Odisee
DE CO-HOGESCHOOL

Embryo / Fetal shielding

- Within 1° beam
- Outside 1° beam
  - *Typical* doses without lead protection
    - X-ray cervical spine, extrimities: < 0.001 mGy
    - X-ray thorax: < 0.002 mGy
    - Fluoro/angio: very low but variable
    - CT thorax, PE: < 1 mGy
      e.g. CT PE without lead apron: 0.17 mGy
      CT PE with lead apron: 0.15 mGy

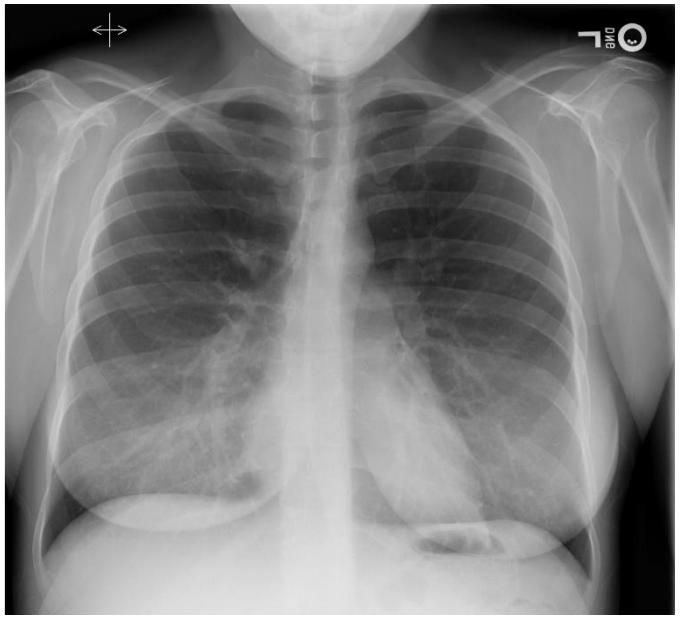

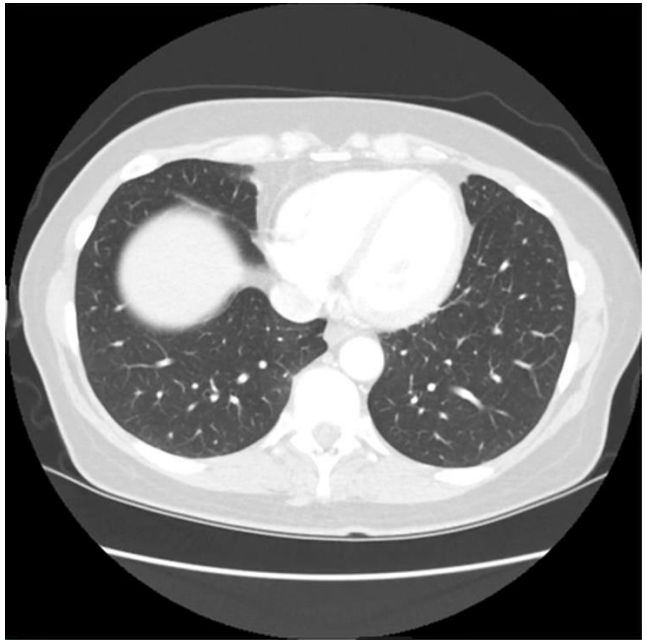

Embryo / Fetal shielding

- Outside 1° beam

Origin of exposure:

Primarily internal scatter

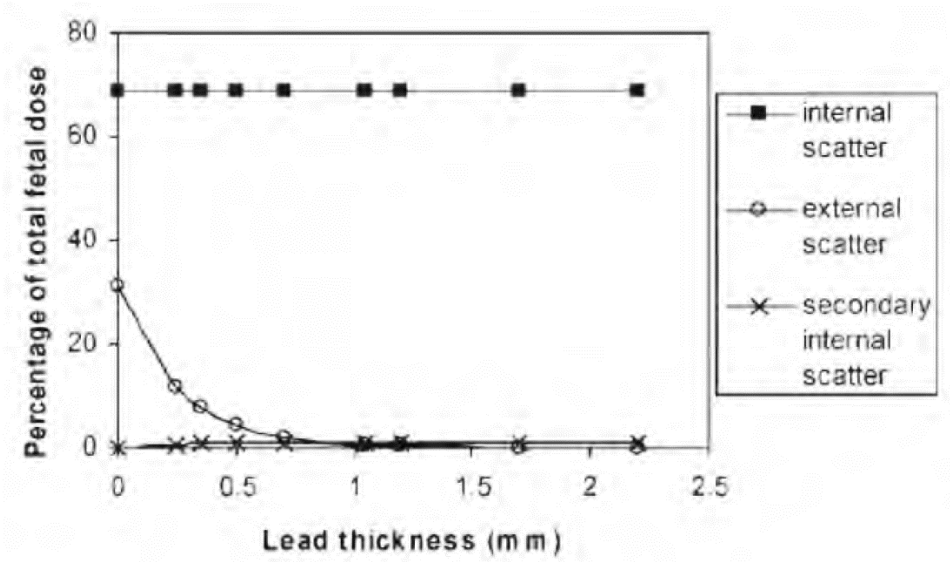

[5]

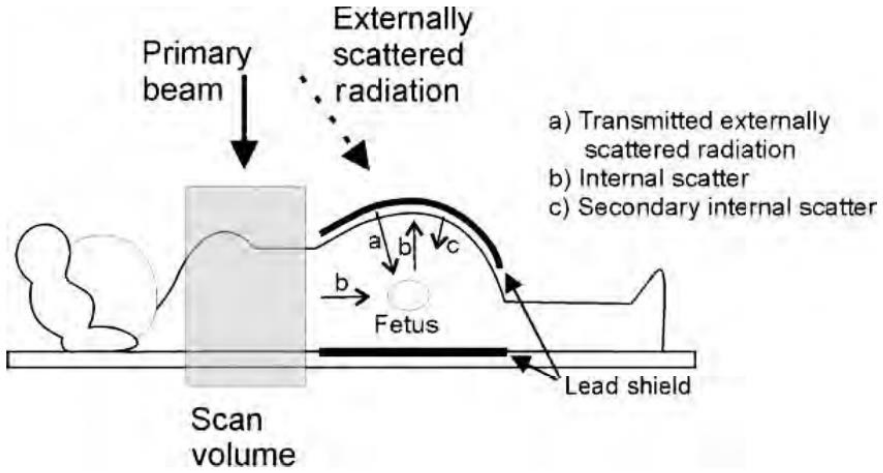

Figure 9.11 Schematic showing the three sources of scattered photons that contribute to the fetal dose from a chest CT scan. (Reproduced from Iball, Kennedy and Brettle 2008.[46])

Shielding of the unborn child: conclusion

[1,5,8]

1. Deterministic effects ~ range of diagnostic doses
   - Absolute value of risk reduction is very limited

2. Could have a negative effect on exam
   - Possibly obstructive for exam
   - High chance on increased dose / repeat exam

3. Cancer risk

Patient’s cancer risk

- Uncertainties
- Balancing risk vs benefits

- Variable for different tissues

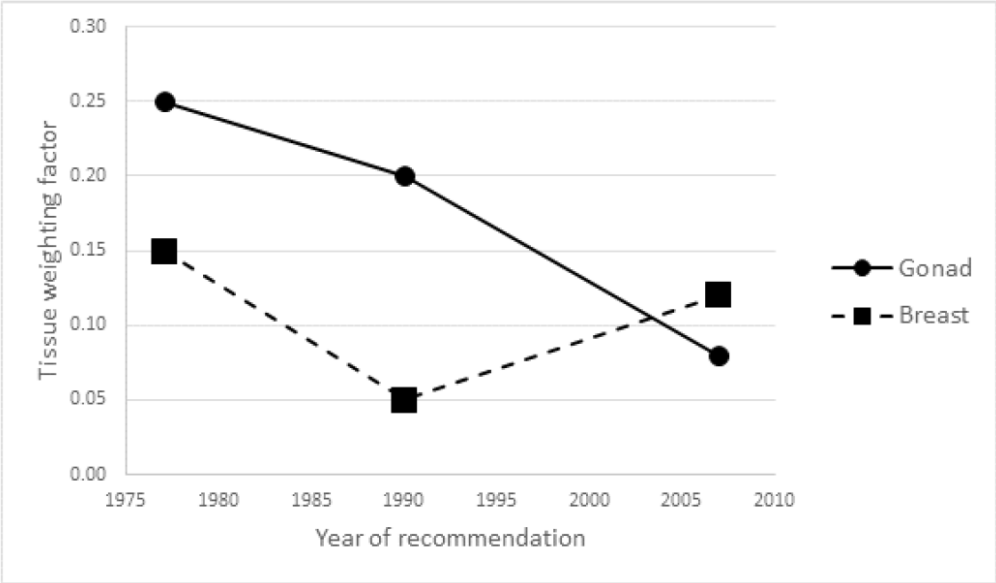

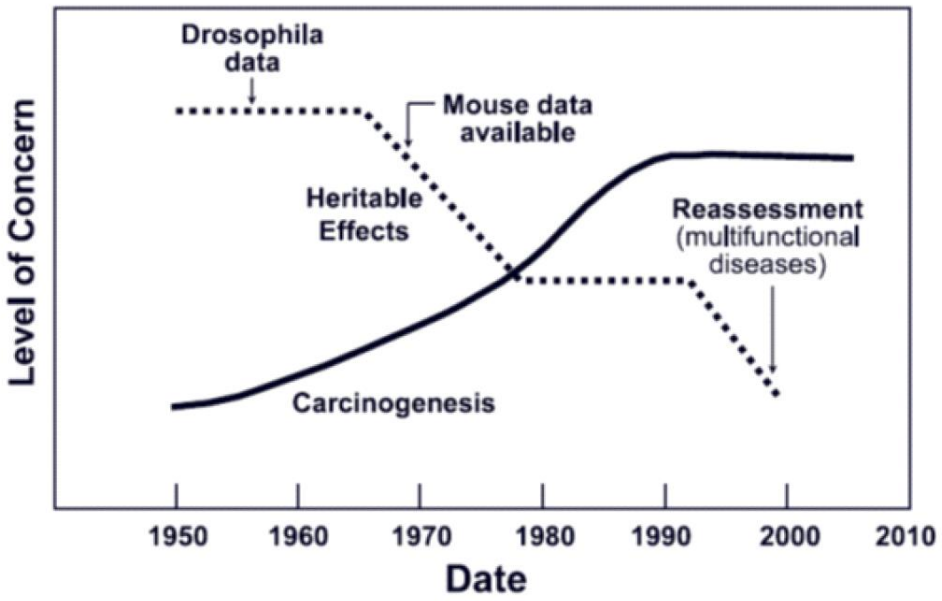

[5]

se an

Patient's cancer risk

Should use May use Not recommended

[5,8]

- Protection of radiosensitive organs
  - Breast 
  - Thyroid 

    * exception: ceph and dental CBCT large FOV units: AP, <5 cm of 1° beam, anatomy not covered, no interference with AEC → involve MPE

    ! Providing: good practice, ALARA, optimized exposure
  - Eye lens 
- Fluoroscopy procedures
  - ! Protective materials for protection of personnel

Cancer risk after exposure in utero

- Conservative estimate
  - 100 mGy fetal dose ~ risk x 2

Fetal dose	Risk of developing childhood cancer	Risk of NOT developing childhood cancer
~0	0.2600 %	99.74 %
0.02 mGy	0.2601 %	99.74 %
0.1 mGy	0.2605 %	99.74 %
1 mGy	0.265 %	99.71 %
10 mGy	0.312 %	99.69 %
100 mGy	0.52 %	99.48 %

[7]

CT PE with vs without lead apron

↕

Weigh against risks of use of shielding

Cancer risk : conclusion

*

[5,8]

1. Increase of cancer risk at diagnostic doses : very low

2. Advantage of (limited) dose reduction << risks associated with use of shielding

4. Communication of radiation risks

Communication

- Different reasons NOT to use gonad or fetal shielding
- **But**:
  - Long tradition
  - Perception of professionals
  - Public perception
- Risks associated with overestimating radiation risks
  - Postponing exams
  - Depriving adequate care
  - Missed or postponed diagnosis
  - Unneccessary fear (parents)

Communication

- Consistent communication & education
  - → doesn't help
  - → possibly obstructive for exam
  - → possibly higher dose

Changing a tradition is not easy…

Communication

Want to know more? FAQs?

- www.aapm.org/cares
- BIR Guidance on using shielding on patients for diagnostic radiology applications + leaflets

References

[1] AAPM PP 32-A: AAPM Position Statement on the Use of Patient Gonadal and Fetal Shielding. (2019). Retrieved from https://www.aapm.org/org/policies/details.asp?id=468&type=PP&current=true

[2] Riaud. First dental radiograph (1896). J. Dent Health 2018; 9(1):33 - 34.

[3] Retrieved from https://www.genetics.org/content/202/2/369 and https://www.embl.org/news/science/what-we-learned-from-fruit-flies .

[4] Hodges PC, Strandjord NM, McCrea A. A testicular shield. JAMA. 1958; 167(10): 1239 – 1240.

[5] The Britisch Institute of Radiology. Guidance on using shielding on patients for diagnostic radiology applications. BIR published online 2020.

[6] Somasundaram E et.al. Achievable dose reductions with gonadal shielding for children and adults during abdominal/pelvic radiographic examinations: A Monte Carlo simulation. Med. Phys. 2020; 47(11): 5514 - 5522.

[7] Retrieved from https://w3.aapm.org/cares

[8] Hiles P, Gilligan P, Damilakis J et al. European consensus on patient contact shielding. Physica Medica 96 (2022): 198-203.

Thank you for your attention!

Odisee
DE CO-HOGESCHOOL

Questions?

Liesbeth Eloot
Liesbeth.Eloot@odisee.be

www.odisee.be

Onderzoek? Navormingsaanbod? Basisopleidingen?